

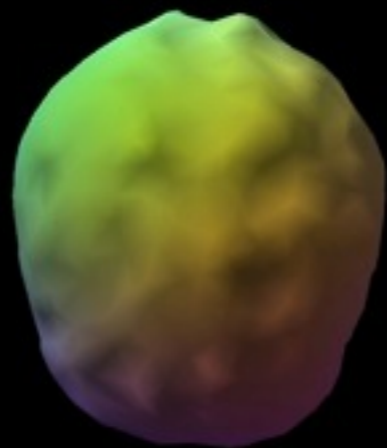
THE BRAIN ACTIVITY OF ADDICTION

# SPECT IMAGING

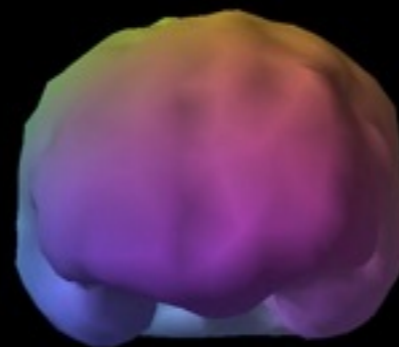
DR. DANIEL AMEN

# NORMAL BRAIN

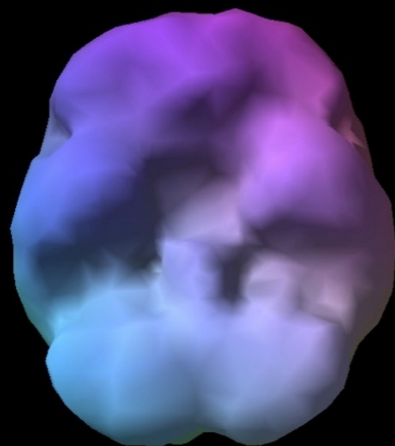
Top-  
down  
surface  
view



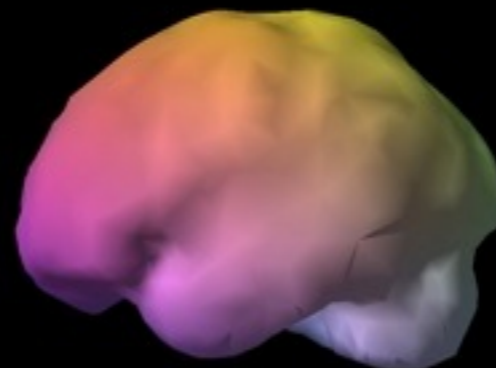
Front-on  
surface  
view



Underside  
surface  
view



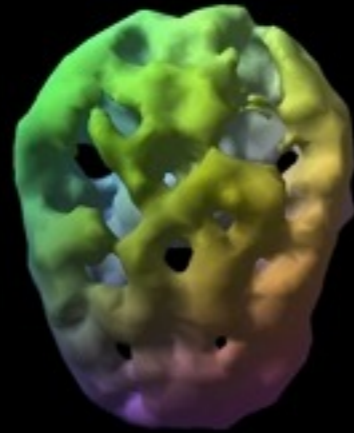
Side  
surface  
view



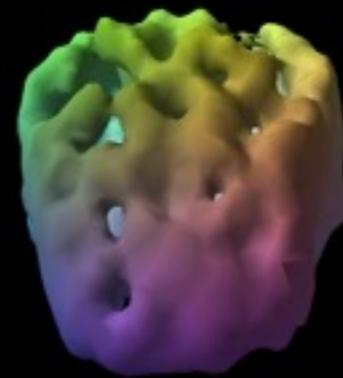
# ALCOHOLIC BRAIN

SEVENTEEN YEARS OF DRINKING

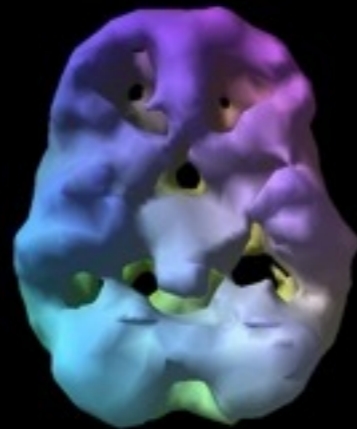
Top-  
down  
surface  
view



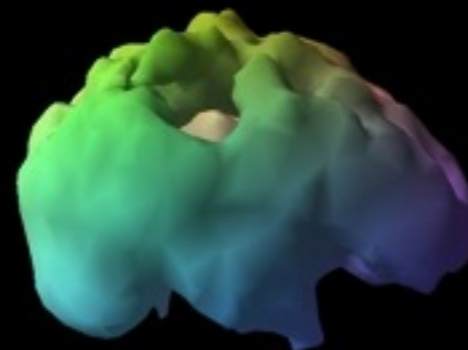
Front-on  
surface  
view



Underside  
surface  
view

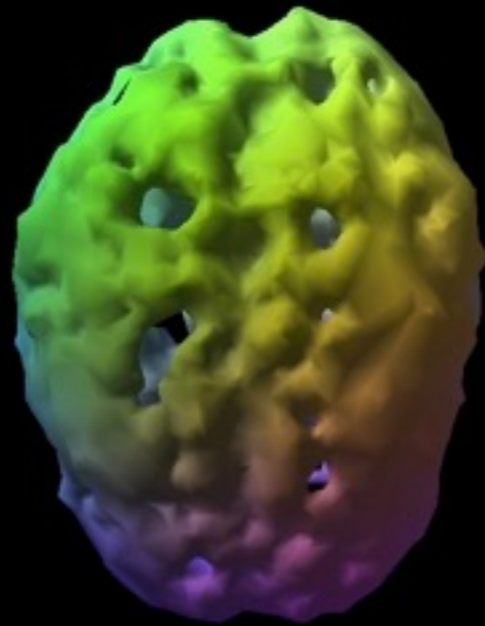


Side  
surface  
view

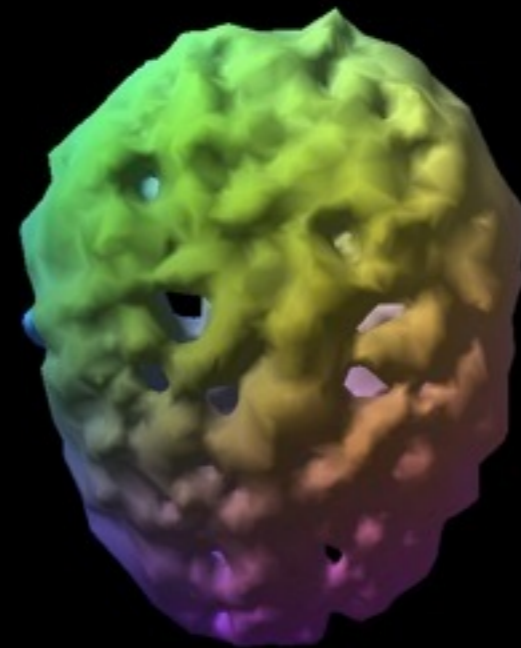


COCAINE

METHAMPHETAMINE

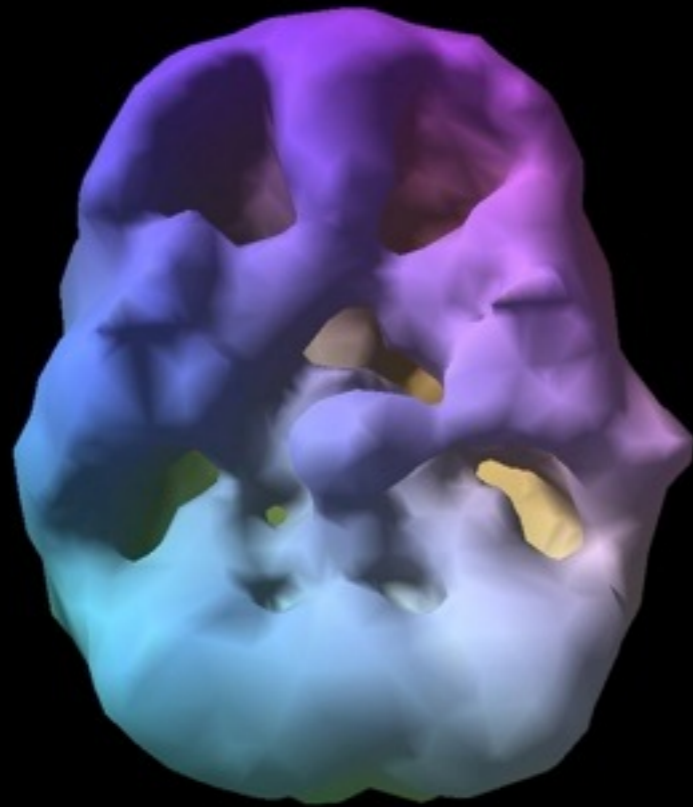


Twenty-four year old.  
Using two years frequently.



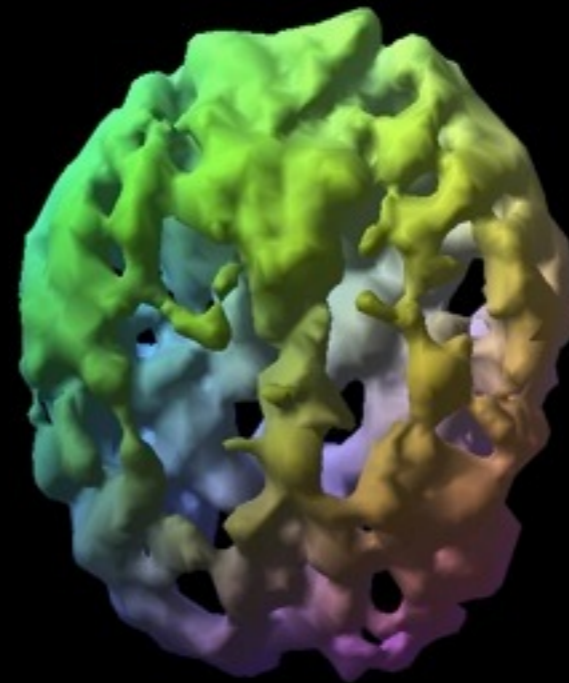
Twenty-eight year old.  
Eight year heavy use.

# MARIJUANA



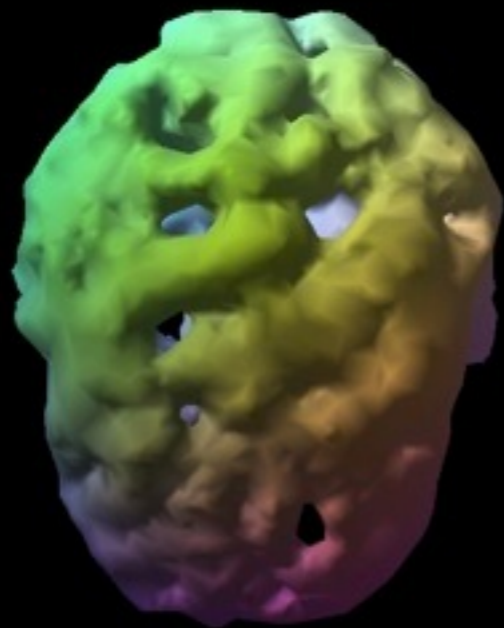
Eighteen year old.  
Using 3 years.  
Four times week.

# OPIATES

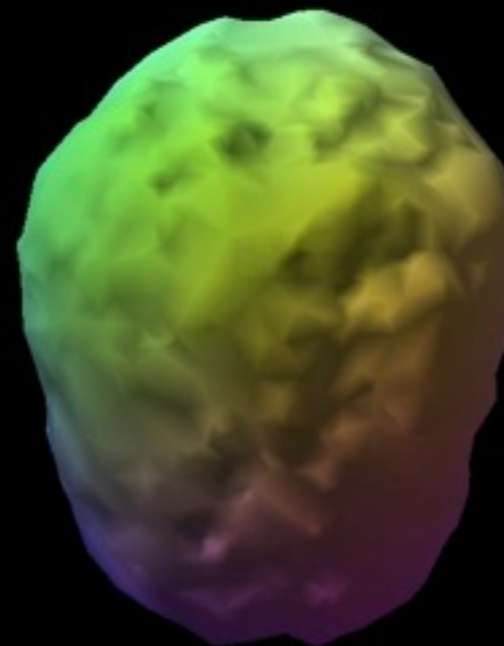


Forty year old.  
Methadone 7 years.  
Previously, heroin 10 years.

# BEFORE & AFTER RECOVERY



Top down surface view  
during addiction.



Same view after one year  
alcohol and drug free.